

# A Canadian center's experience on whole-gland salvage therapy for radio-recurrent prostate cancer with various modalities

Joseph L. Chin<sup>1</sup>, J. Jesus Cendejas-Gomez<sup>2</sup>, Max Peters<sup>2</sup>

<sup>1</sup>Division of Surgical Oncology, Western University, London, ON, Canada; <sup>2</sup>Department of Radiotherapy, Utrecht University, Utrecht, Netherlands

Cite as: Chin JL, Cendejas-Gomez JJ, Peters M. A Canadian center's experience on whole gland salvage therapy for radio-recurrent prostate cancer with various modalities. *Can Urol Assoc J* 2023;17(12):425-31. <http://dx.doi.org/10.5489/cuaj.8331>

Published online August 29, 2023

## INTRODUCTION

Salvage radical prostatectomy for localized radio-recurrent prostate cancer had historically, in the 1980s and 1990s, been associated with relatively high morbidity. Thus, there was an impetus to explore the role of minimally invasive ablative therapies for this patient population. To review the Canadian experience of salvage ablative therapy for radio-recurrent prostate cancer, this article chronicles the quarter-century results of whole-gland salvage ablation therapies at one academic center, Western University (UWO), with emphasis on cryoablation, high-intensity focused ultrasound (HIFU), and interstitial laser photodynamic therapy (PDT). As well, recent developments in other salvage techniques and advanced functional imaging will be reviewed, and the evidence for and increasing acceptance of focal salvage therapy will be briefly discussed.

## HISTORICAL NOTES

Cryosurgery, or cryoablation, for the prostate was initially used for benign prostatic hyperplasia and subsequently extended to prostate cancer in the 1960s.<sup>1-3</sup> Initially, the treatment, with a large cryoprobe applied directly on the prostate via a perineal incision, was plagued by a high urethro-rectal and urethro-cutaneous fistula rates.

## Perfect storm for prostate ablation

A fortunate happenstance occurred in the 1990s with 1) improved prostate imaging, championed by Lee et al, using a transrectal probe for visualization and biopsy,<sup>4</sup> facilitating precise cryoprobe placement and intraoperative monitoring and control of the freezing process; 2) improvement in techniques for percutaneous renal stone treatment (e.g., Seldinger technique and Amplatz dilators), paving the way for transperineal prostate access and image-guided cryoprobe insertion; and 3) advances in cryobiology and cryogenics, aiding transition from liquid nitrogen-based freezing to argon-based technology, applying the Joule-Thompson principle. The later-generation cryo-systems have further improved the cytotoxic capabilities, as well as safety and precision of prostate cryoablation<sup>5,6</sup>

Building on the initial experience of Onik et al, on two-dimensional transrectal ultrasound (2D-TRUS) for probe placement and intraoperative monitoring,<sup>7,8</sup> and to circumvent the limitation of visualizing a three-dimensional (3D) disease process with 2D imaging, 3D ultrasound (US) imaging was incorporated into the UWO whole-gland salvage ablation procedures. The custom-designed software system produced 3D prostate reconstruction, permitting intraoperative verification of cryoprobe placement in transverse, sagittal, and the previously unavail-

able coronal views of the prostate<sup>9</sup> (Figure 1) ("Artemis system," Eigen Grass Valley, CA, U.S.).

## SALVAGE WHOLE GLAND CRYOABLATION

A prospectively maintained database of 187 patients undergoing salvage whole-gland ablation at UWO was established in 1995.<sup>10</sup> All patients had biopsy-proven radio-recurrent disease and negative metastatic work-up. Routine serial post-cryoablation biopsy (at six, 12, and 24 months) showed 23% of patients had positive biopsies.<sup>10</sup> Cancer persistence/recurrence was documented primarily at the apex (51.5%), base (21.2%), and seminal vesicles (18.2%).<sup>11</sup> With median followup at 149 months, 12-year overall survival (OS) was 56%, metastasis-free survival (MFS) 78%, and disease-specific survival (DSS) 81%,<sup>12</sup> while biochemical disease-free survival (BDFS) was 36% (Table 1).

Pre-radiation Gleason score and grade, pre-radiation T stage, and pre-cryoablation prostate-specific antigen (PSA) levels were identified as predictors of cancer-specific survival (CSS), while PSA nadir post-cryoablation was found to be prognostic. At 12-year median followup, 49% of the patients were free from androgen deprivation therapy (ADT), and for those who did progress onto requiring ADT, the median time from time of cryoablation to commencement of ADT was 101 months.<sup>13</sup>

A combined analysis with a comparable database from MD Anderson Cancer Center comprised 268 patients with complete data. With

a median followup of 10.3 years, 223 (74.3%) patients had experienced complications, including 168 Clavien I-II events and 55 Clavien III events. At 10 years, 69% had freedom from ADT and 76% had freedom from castrate-resistant prostate cancer (CRPC). The 10-year CSS rate was 81%, and the 10-year OS rate was 77%. A pre-salvage PSA >10 ng/ml was associated with an increased risk of developing CRPC and initiation of ADT but was not associated with DSS or OS.<sup>14</sup>

Hence, whole-gland salvage cryotherapy for radio-recurrent cancer can achieve long-term DSS and OS, as well as longer freedom from ADT and CRPC. It should also be noted that results from the aforementioned series were derived from older cryo-technology and historic, likely less stringent, patient selection criteria, as well as older radiotherapy techniques and less sophisticated image guidance. Improved results should be expected with more contemporary technology and techniques.

### SALVAGE HIGH-INTENSITY FOCUSED ULTRASOUND ABLATION

High-intensity focused ultrasound (HIFU) was used as an ablative modality for benign prostatic hyperplasia (late 1980s) and subsequently for prostate cancer (early 1990s).<sup>15-17</sup> Experience with primary whole-gland prostate ablation has been reported by many groups, employing two different HIFU systems (Ablatherm, EDAP-TMS; and Sonablate, US HIFU). A whole-gland salvage therapy program was established at UWO in 2004. With median followup of five years on 81 patients,

CSS at five years was 94.4%, whereas OS was 88%, and five-year BDFS by Phoenix criterion was 53%.<sup>17</sup> Serial biopsy following salvage whole-gland HIFU yielded a 24% positive rate, although histologic confirmation of secondary treatment failure (post-radiotherapy and subsequently post-HIFU) was challenging for pathologists.<sup>18</sup>

### COMPLICATIONS FROM SALVAGE WHOLE-GLAND CRYOABLATION AND HIFU

Complications, consistent with published results in the setting of localized prostate cancer, included rectourethral fistula (3.7%) (all three patients were within the initial cohort of 20 patients), severe incontinence (3.7%), and bladder neck obstruction necessitating transurethral resection (2.4%).<sup>19</sup> Based on our small combined experience from Canada and U.K., men who had radio-recurrent cancer after low-dose-rate brachytherapy, as opposed to external beam radiotherapy, appeared to have a higher complication rate when undergoing whole-gland salvage HIFU.<sup>20</sup> The authors opined that more extensive tissue ablative damage with brachytherapy compromised US imaging and targeting, leading to poorer results.

In a single-center analysis of treatment-related morbidity, Clavien grade II and grade IIIb complications were significantly lower after the initial 60 whole-gland cryoablation cases. HIFU had a statistically significant ( $p=0.0001$ ) lower complication rate (both Clavien II and III) compared to cryoablation. The rate of urinary retention was significantly higher in the cryoablation group compared to the HIFU cohort ( $p=0.0005$ ); how-

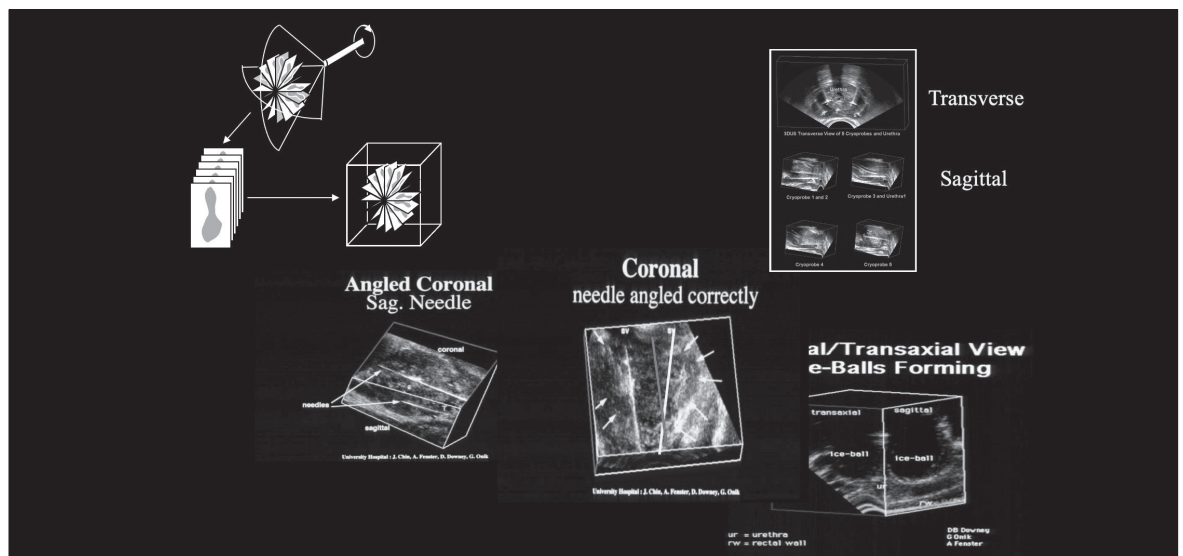


Figure 1. Custom-designed software system for 3D prostate reconstruction.

**Table 1. Salvage whole gland cryoablation, comparison of whole-gland salvage cryoablation (at UWO) and the combined analysis between UWO and MD Anderson Cancer Center**

	UWO	Combined UWO/MD Anderson
Database	Median followup =12.4 years	Median followup =10.3 years
	n=187	n=268
Overall survival	56% (@12.4 y)	77% (@10.3 y)
Cancer-specific survival	81%	81%
Metastasis-free survival	78%	
Biochemical disease-free survival	36%	
Freedom from ADT	49% (@12.4 y)	69% (@10.3 y)
Freedom from CRPC		76% (@10.3 y)

ADT: androgen deprivation therapy; CRPC: castration-resistant prostate cancer; UWO: Western University.

ever, the rates of severe incontinence (range 1.5–5%), need for surgical intervention (1.5%), and recto-urethral fistulae (range 1.5–3%), were not statistically different between the two ablative modalities in whole-gland treatment.<sup>21,22</sup>

In the UWO single-center analysis of treatment-related morbidity, Clavien-Dindo grade I and II complications are listed in the initial “earlier” (1995–1998) cryoablation patients (group 1), the “later” (2002–2004) cryoablation (group 2), and the HIFU patients (group 3) (n=65 in each group) (Table 2). There was one grade IVa complication in group 3 (intra-peritoneal bladder rupture requiring laparotomy, secondary to blocked suprapubic catheter). HIFU had a statistically significant lower (p=0.0001) Clavien I and II complication rate compared to cryoablation. The rate of urinary retention was significantly higher in the cryoablation group compared to the HIFU cohort (p=0.0005); however, the rates of severe incontinence (range 1.5–5%), need for surgical intervention (1.5%), and recto-urethral fistulae (range 1.5–3%), were not statistically different between the two ablative modalities in whole-gland treatment.<sup>21,22</sup>

**COMPARISON OF SALVAGE ABLATION WITH SALVAGE PROSTATECTOMY**

A bi-institutional, retrospective comparison on outcomes was conducted between 251 salvage prostatectomy patients at the Mayo Clinic and 187 salvage cryoablations at UWO between 1988 and 2016, with respective median followup of 118 (interquartile range [IQR] 136.6

months and 105 (IQR 100.3) months, respectively.<sup>23</sup> Ten-year biochemical relapse-free survival (BRFS) was higher following surgery (44.8% vs. 31.9%, p=0.001), while MFS was greater in the salvage cryoablation group (83% vs. 73%, p=0.02). Nevertheless, no significant differences were noted for 10-year CSS (75.5% vs. 82.5%, p=0.06) or OS (p=0.39). In this analysis, salvage prostatectomy was more effective in deferring or obviating subsequent ADT; however, salvage cryoablation had lower overall treatment-related morbidity.

In another bi-institutional analysis, 378 patients were identified by propensity score matching at Memorial Sloan Kettering Cancer Center (207 salvage prostatectomy) and UWO (180 salvage ablation, either cryoablation or HIFU).<sup>24</sup> The cohorts had comparable pre-salvage PSA, Gleason score, and primary radiation treatment. In the group of 88 patients who subsequently developed metastasis, the median followup time was 4.6 years from therapy. For the entire combined cohort, there was a non-significantly higher rate of CSS (hazard ratio [HR] 1.02, 95% confidence interval [CI] 0.51, 2.06, p=0.9) and improved MFS (HR 0.71, 95% CI 0.44, 1.13, p=0.15) among patients undergoing salvage ablation compared to patients undergoing salvage prostatectomy. There was a lower rate of ADT use in the salvage prostatectomy compared to the ablation group, although this did not meet conventional levels of significance (HR 1.42 95% CI 0.97, 2.08, p=0.068).

**Table 2. Clavien-Dindo grade complications, UWO single-center analysis of treatment-related morbidity**

	Group 1 Cryotherapy “earlier” (1995–1998) n=65	Group 2 Cryotherapy “later” (2002–2004) n=65	Group 3 HIFU (2006–2011) n=65
Clavien-Dindo grade			
I–II	78	49	13
IIIa	2	5	4
IIIb	8	2	3
IVa	0	0	1

Clavien-Dindo complications of the initial “earlier” (1995–1998) cryoablation patients (group 1), the “later” (2002–2004) cryoablation (group 2), and HIFU patients (group 3). HIFU: high-intensity focused ultrasound. HIFU: high-intensity focused ultrasound; UWO: Western University.

### **SALVAGE INTERSTITIAL LASER WHOLE-GLAND ABLATION**

Phase 1 and 2 trials of another energy-based ablative modality, photodynamic therapy (PDT) with interstitial laser, were initiated by Trachtenberg et al. **TOOKAD WST 09** (padoporfin), a hydrophobic palladium-bacteriopheophorbide molecule is a photosensitizer and was first used to mediate vascular-targeted PDT (VTP) as salvage whole-gland ablative treatment.<sup>25,26</sup> When activated by a 763 nm laser light, **TOOKAD-VTP** was shown to be cytotoxic by causing large avascular regions in previously irradiated prostates. Initial results on 28 patients (from University of Toronto, McGill, and UWO) showed magnetic resonance imaging (MRI) devascularization response ranging from 7–84% of the prostate volume. An average PSA decrease of 76% (range 66–95%) from baseline was recorded, with several patients achieving undetectable PSA. Biopsy response correlated strongly with the degree of MRI devascularization. Response correlated directly with energy delivered with an apparent threshold of approximately 30 J/cm<sup>3</sup>. Voiding dysfunction was manageable in all patients except urethro-rectal fistulae developed in two of the earliest patients.

### **POTENTIAL ROLE OF NEXT-GENERATION FUNCTIONAL IMAGING FOR PROSTATE CANCER AND SALVAGE ABLATION**

Advancements in multiparametric MRI (mpMRI) and prostate-specific membrane antigen positron emission tomography (PSMA-PET) have provided superior intraprostatic anatomic details, facilitating prostate ablation by improving the identification of undetected and atypical lesions in the face of standard of care (SOC) imaging.<sup>27-29</sup> By incorporating multimodal image fusion (PET/CT, PET/MRI) in the treatment algorithm, evaluation of biochemical recurrence, staging, and treatment planning for radio-recurrent prostate cancer has been facilitated.<sup>27</sup> Moreover, PSMA-PET has allowed surgeons to exclude candidates who previously have undetected occult extraprostatic disease. Metser et al reported additional sites of disease detected by PSMA-PET compared with SOC imaging in approximately 60% patients with biochemical recurrence and suspected low-volume recurrent disease. Furthermore, 49% of this population had localized regional recurrence without distant disease, rendering them potentially eligible for salvage focal ablative therapy.<sup>30</sup>

PSMA PET/MRI has shown higher sensitivity for tumor detection than mpMRI and PSMA PET/CT (66%, 92% respectively, compared to 98% for PSMA PET/

MRI),<sup>31</sup> especially in the context of biochemical recurrence. Further experience from ongoing investigations will hopefully determine the best form of imaging prior to focal salvage ablation. If “next-generation” functional imaging can optimize patient selection for salvage therapy, and if biopsy confirmation of persistent/recurrent cancer can be obviated, therapeutic burden of salvage therapy will be significantly reduced.

### **FROM WHOLE-GLAND PRIMARY AND SALVAGE ABLATION TO FOCAL PRIMARY ABLATION, EVENTUALLY TO FOCAL SALVAGE THERAPIES**

Building on the experience from whole-gland ablation by HFIU, Ahmed et al first reported on focal therapy in 42 men who had either unifocal or multifocal localized cancer in the primary setting.<sup>32</sup> Since the imaging and therapeutic elements of HIFU are integrated in a single US crystal, there is minimal interphase between these two components. HIFU has the advantage of being amenable to precise planning and demarcation for focal as opposed to whole-gland ablation. Similarly, experience with focal primary cryoablation is rapidly accumulating.<sup>33,34</sup>

There have been several phase 2 studies using hydrophilic **TOOKAD WST 11** (padeloporfin) primary focal therapy (FT) or hemi-ablation<sup>31,35</sup> in low-risk cancer, and a phase 3 trial of partial ablation with PDT randomized against active surveillance. The latter phase 3 trial concluded lower conversion to radical therapy for the PDT cohort, thus overall reducing treatment burden.<sup>36</sup>

### **OTHER ABLATIVE ENERGIES: INITIALLY USED FOR PRIMARY TREATMENT**

#### **Focal irreversible electroporation**

Focal irreversible electroporation (IRE) employs repetitive short electrical pulses delivered via transperineal electrodes, which cause alterations in the stability of the cell membrane, inducing nanopores and secondarily causing cell death.<sup>37,38</sup> Preclinical and subsequent clinical studies have demonstrated its feasibility and safety as primary focal therapy for primary prostate cancer, demonstrating adequate oncologic control, good quality of life (QoL), and limited toxicity. Van de Bos and colleagues demonstrated, in 63 patients, no high-grade adverse events, no significant change in QoL from baseline in physical, mental, and urinary domains, and a decline in PSA of 70% at six and 12 months of followup.<sup>38</sup> Blazavski et al reported experience in 123

patients with localized clinically significant prostate cancer, showing satisfactory short-term oncologic outcome with failure-free survival of 96.75% at three years, MFS of 99%, and OS of 100%.<sup>39</sup>

Evidence with focal salvage IRE is very limited, although feasibility, safety, oncologic control, and good short-term QoL were demonstrated. Scheltema et al reported on 18 patients who achieved median nadir PSA of 0.39 g/L after salvage IRE, with no high-grade adverse events or significant decline in various QoL domains. Three patients developed biochemical failure and PSMA PET-CT showed, respectively, local recurrence, bone metastases, and a solitary pelvic lymph node. Two patients developed metastatic disease during followup, and eight of 10 patients had negative followup biopsies.<sup>40</sup>

### Microwave focal therapy

Microwave focal therapy (MFT) employs tissue heating, which results in cell death by causing cellular membrane or intracellular structure membrane damage, as well as by denaturing and coagulating structural proteins.<sup>41,42</sup> Thermal energy is delivered via laser fibers inserted interstitially. Sherar et al first reported on MFT for primary prostate cancer in a small cohort in 2001, concluding it is a safe option for primary prostate cancer.<sup>41</sup> Other investigators have also reported safety and feasibility with primary MFT in localized prostate cancer in small studies.<sup>42,43</sup> For radio-recurrent cancer, Sherar et al also reported patient safety, with a medium DFS similar to that for cryotherapy in the same context, especially for those with PSA nadir <0.5 ng/ml.<sup>44</sup>

### Transurethral ultrasound ablation

In 2013, MRI-guided transurethral ultrasound ablation (TULSA) was introduced as a Canadian technology that integrates quantitative image-based planning, monitoring, and treatment control with transurethral delivery of therapeutic US to ablate prostate tissue through thermal coagulation<sup>45</sup> via directional (planar, not focused) HIFU energy into the adjacent prostate, theoretically tailored to patient-specific anatomy and pathology.

The early-phase studies were primary ablation, with a phase 1 trial of 30 low-risk patients, and a subsequent 13-center (including University of Toronto and UWO) phase 2 study on 115 patients with low- and intermediate-risk disease.<sup>46,47</sup> The phase 1 study reported no severe adverse events. Urinary, bowel, and erectile function recovered by one year and were stable at three years. The PSA level decreased 95% to a median nadir of 0.34 ng/ml in both the phase 1 and 2 trials.

In the latter, of 111 men with 12-month biopsy data, 65% had no evidence of cancer. Among a subset with pretreatment grade group 2 disease, 52/68 (79%) were free of grade group 2 disease.

The promising results of TULSA in primary ablation have served as the evidentiary foundation for application to post-radiotherapy salvage treatment, especially since no energy is directed through the rectum, thus potentially reducing the risk of prostate-rectal fistula, arguably the most debilitating complication of ablative therapies, and especially in the salvage situation. To date, no prostate-rectal fistulae has been reported in over 3000 patients treated worldwide with TULSA. Thus far, there have been only two small series pertaining to salvage TULSA.<sup>48,49</sup> In one study of 11 patients, no significant adverse events were reported, and eradication of disease in the treated zone was documented in 10 of 11 patients.<sup>49</sup> Further experience will hopefully validate the use of TULSA as a safe salvage therapeutic modality.

### FOCAL SALVAGE THERAPY IS HERE TO STAY

Studies have shown recurrent prostate cancer to behave more unifocally compared to the multifocal character in the primary setting,<sup>49</sup> rendering focal salvage therapy targeting only the recurrent lesion more attractive, with the objective of deferring systemic treatment and potentially curing a subset of patients.

As alluded to, several modalities previously used for primary and salvage whole-gland treatments are now being applied to focal salvage therapy. Along with focal brachytherapy, primary focal cryotherapy and HIFU are now the most common ablative modalities; however, availability of focal salvage therapy is confined to relatively few centers with specialized equipment and expertise. Case series typically include fewer than 50 patients and, overall, >95% of patients receiving (deferred) ADT. Furthermore, inclusion criteria vary from low- to higher-risk populations between studies and there have been no formal comparative studies thus far.

Regarding focal brachytherapy, which has emerged as a viable focal salvage therapy, results from patients who have had prior low-dose rate (LDR) radioactive implant treatment have a higher biochemical recurrence-free rate (approaching 80% at four years) compared to patients with prior high-dose rate (HDR) treatment (biochemical recurrence-free rate of 45% at five years).<sup>50-52</sup> One likely explanation is patient selection bias; patients presenting initially with higher-risk cancers (e.g., T3b) would have been treated with HDR



since they would not be eligible for the LDR approach. Another very promising approach is focally ablating recurrent prostate cancer using (external) stereotactic radiotherapy techniques, with radiation delivery precision increasing using MR-guided systems.<sup>53</sup> One key limitation of these recent studies is their small sample size. Nevertheless, the studies show comparable and promising tumor control and toxicity rates, with no discernable differences among modalities.

## CONCLUSIONS

Long-term experience (locally and elsewhere) from salvage whole-gland ablation with cryosurgery exceeding 12 years and intermediate-term results from HIFU have shown that local salvage ablation following failure of radiotherapy is a viable alternative therapeutic approach, with CSS and MFS of approximately 80%, and BDFS of 35%. More importantly, freedom from ADT was 49% at 12 years.<sup>14,17,22,24</sup>

Advancements in imaging and ablative technologies have led to promising focal salvage therapies, albeit still with limited oncologic and functional outcome follow-up. Further larger, confirmatory results will enable incorporation of advanced functional imaging, as well as possibly using different ablative modalities into the patient selection algorithm for salvage ablation therapy, especially with focal salvage therapy. For instance, an “à-la-carte” approach to focal therapy proposed by Sivaraman et al based on the target location (e.g., HIFU for posterior, cryoablation for anterior and brachytherapy for apical lesions)<sup>54</sup> may be considered in selected future situations.

**COMPETING INTERESTS:** Dr. Chin has been an advisory board member for Abbvie, Johnson & Johnson, TerSera, and Theralase; a consultant for Profound; and has participated in clinical trials supported by Astellas, Janssen, Pfizer, and Profound. Dr. Peters has received a grant by the Dutch Cancer Society (KWF/Kankerbestrijding) [grant number 10932]. Dr. Cendejas-Gomez does not report any competing personal or financial interests related to this work.

This paper has been peer-reviewed.

## REFERENCES

- Gonder MJ, Soanes WS, Shulman S. Cryosurgical treatment of the prostate. *Invest Urol* 1966;3:372.
- Flocks RH, Nelson CM, Boatman DL. Perineal cryosurgery for prostate cancer. *J Urol* 1972;108:933. [https://doi.org/10.1016/S0022-5347\(17\)60910-8](https://doi.org/10.1016/S0022-5347(17)60910-8)
- Megallani MR, Gursel EO, Veenema RJ. Closed perineal cryosurgery in prostatic cancer. New probe and technique. *Urology* 1974;4:220. [https://doi.org/10.1016/0090-4295\(74\)90340-9](https://doi.org/10.1016/0090-4295(74)90340-9)
- Lee L, Tiorp-Pedersen ST, Siders DB. Use of transrectal ultrasound in diagnosis, guided biopsy, staging and screening of prostate cancer. *Urol* 1989;33:7. [https://doi.org/10.1016/S0090-4295\(89\)80002-0](https://doi.org/10.1016/S0090-4295(89)80002-0)
- Han K-R, Belldgrun A. Third generation cryosurgery for primary and recurrent prostate cancer. *BJU* 2004;93:14. <https://doi.org/10.1111/j.1464-410X.2004.04547.x>
- Mouraviev V, Spiess P, Jones JS. Salvage cryoablation for locally recurrent prostate cancer following primary radiotherapy. *Eur Urol* 2012;61:1204. <https://doi.org/10.1016/j.eururo.2012.02.051>
- Onik G. Percutaneous image-guided prostate cancer treatment: cryoablation as a successful example. *Tech Vasc Interv Radiol* 2007;10:149-58. <https://doi.org/10.1053/j.tvir.2007.09.007>
- Chin JL, Downey DB, Mulligan M, et al. Three-dimensional transrectal ultrasound guided cryoablation for localized prostate cancer in nonsurgical candidates: a feasibility study and report of early results. *J Urol* 1998;159:910-4. [https://doi.org/10.1016/S0022-5347\(01\)63769-8](https://doi.org/10.1016/S0022-5347(01)63769-8)
- Chin JL, Downey DB, Onik G, et al. Three-dimensional prostate ultrasound and its application to cryosurgery. *Tech Urol* 1996;2:187-93.
- Siddiqui KM, Billia M, Al-Zahrani A, et al. Long-term oncologic outcomes of salvage cryoablation for radio-recurrent prostate cancer. *J Urol* 2016;196:1105-11. <https://doi.org/10.1016/j.juro.2016.04.080>
- Ng CK, Touma NJ, Chalasani V, et al. The pattern of prostate cancer local recurrence after radiation and salvage cryoablation. *Can Urol Asso J* 2011;5:125-8. <https://doi.org/10.5489/cuaj.09116>
- Siddiqui KM, Billia M, Al-Zahrani A, et al. Long-term oncologic outcomes of salvage cryoablation for radio-recurrent prostate cancer. *J Urol* 2016;196:1105-11. <https://doi.org/10.1016/j.juro.2016.04.080>
- Nair S, Peters M, Abed H, et al. Tumor control outcomes of salvage cryotherapy for radio-recurrent prostate cancer at median 12 years follow-up. *Eur Urol Suppl* 2019;18:e869. [https://doi.org/10.1016/S1569-9056\(19\)30634-7](https://doi.org/10.1016/S1569-9056(19)30634-7)
- Chin JL, Lavi A, Metcalfe MJ, et al. Long-term outcomes of whole gland salvage cryotherapy for locally recurrent prostate cancer following radiation therapy: A combined analysis of two centres. *J Urol* 2021;206:646 <https://doi.org/10.1097/JU.0000000000001831>
- Foster RS, Bihrlé R, Sanghvi NT, Fry FJ, Donohue JP. High-intensity focused ultrasound in the treatment of prostatic disease. *Eur Urol* 1993;23:29-33. <https://doi.org/10.1159/000474676>
- Madersbacher S, Pedevilla M, Vingers L, Susani M, Marberger M. Effect of high-intensity focused ultrasound on human prostate cancer in vivo. *Cancer Res* 1995;55:3346-51.
- Siddiqui KM, Billia M, Arifin A, et al. Pathological, oncologic and functional outcomes of a prospective registry of salvage high-intensity focused ultrasound ablation for radiorecurrent prostate cancer. *J Urol* 2017;197:97-102. <https://doi.org/10.1016/j.juro.2016.06.092>
- Billia M, Siddiqui KM, Chan S, et al. Assessment of histopathological features of needle biopsy in recurrent prostate cancer following salvage high-intensity focused ultrasound. *Can Urol Assoc J* 2016;10:416-422. <https://doi.org/10.5489/cuaj.3918>
- Crouzet S, Chapelon JY, Rouviere O, et al. Whole gland ablation of localized prostate cancer with high-intensity focused ultrasound: Oncologic outcomes and morbidity in 1002 patients. *Eur Urol* 2014;65:907-914. <https://doi.org/10.1016/j.eururo.2013.04.039>
- Yutkin V, Ahmed HU, Donaldson I, et al. Salvage high-intensity focused ultrasound for patients with recurrent prostate cancer after brachytherapy. *Urology* 2014;84:1157-62. <https://doi.org/10.1016/j.jurology.2014.06.054>
- Siddiqui KM, Billia M, Williams A, et al. Comparative morbidity of ablative energy-based salvage treatments for radio-recurrent prostate cancer. *Can Urol Assoc J* 2015;9:325-9. <https://doi.org/10.5489/cuaj.3113>
- Nair S, Peters M, Kurver P, et al. Long-term outcomes of two ablation techniques for treatment of radio-recurrent prostate cancer. *Pros Can Pros Dis* 2021;24:186-92. <https://doi.org/10.1038/s41391-020-00265-5>
- Nair S, Lyon T, Dewar M, et al. Salvage cryotherapy versus salvage radical prostatectomy for radio-recurrent prostate cancer: Long-term oncologic outcomes. *Eur Urol Suppl* 2019;18:e872. [https://doi.org/10.1016/S1569-9056\(19\)30636-0](https://doi.org/10.1016/S1569-9056(19)30636-0)
- McPherson V, Nair SM, Tin AL, et al. Comparison of salvage prostatectomy vs. salvage ablative therapy for biopsy proven radio-recurrent localized prostate cancer. *Can Urol Assoc J* 2023 October 23; Epub ahead of print. <http://dx.doi.org/10.5489/cuaj.8373>
- Davidson S, Weersink R, Haider MA, et al. Treatment planning and dose analysis for interstitial photodynamic therapy of prostate cancer. *Phys Med Biol* 2009;54:2293-2313. <https://doi.org/10.1088/0031-9155/54/8/003>
- Trachtenberg J, Weersink RA, Davidson SR, et al. Vascular-targeted photodynamic therapy (padoporphin, WST09) for recurrent prostate cancer after failure of external beam radiotherapy: A study of escalating light dose. *BJU Int* 2008;102:556-62. <https://doi.org/10.1111/j.1464-410X.2008.07753.x>
- Abecassis JP, Ghazazi N, Peyromoure M, et al. Prostate imaging: Contribution of PET PSMA and MRI. *Cancer Radiother* 2020;24:423-8. <https://doi.org/10.1016/j.canrad.2020.06.002>

28. Haj-Hamed M, Karivedu V, Sidana A. Salvage treatment for radio-recurrent prostate cancer: a review of literature with focus on recent advancements in image-guided focal salvage therapies. *Int Urol Nephrol* 2019;51:1101-6. <https://doi.org/10.1007/s11255-019-02114-4>
29. Manfredi C, Fernández-Pascual E, Linares-Espínós E, et al. New frontiers in focal therapy for prostate cancer: Prostate-specific membrane antigen positron emission tomography/magnetic resonance imaging. *World J Clin Oncol* 2021;12:61-8. <https://doi.org/10.5306/wjco.v12.i2.61>
30. Metser U, Zukotynski K, Mak V, et al. Effect of 18F-dcfpyl PET/CT on the management of patients with recurrent prostate cancer: Results of a prospective multicenter registry trial. *Radiology* 2022;303:414-22. <https://doi.org/10.1148/radiol.211824>
31. Taneja SS, Bennett J, Coleman J, et al. Final results of a phase 1/2 multicenter trial of WST11 vascular targeted photodynamic therapy for hemi-ablation of the prostate in men with unilateral low-risk prostate cancer performed in the United States. *J Urol* 2016;196:1096-104. <https://doi.org/10.1016/j.juro.2016.05.113>
32. Ahmed HU, Hindley RG, Dickinson L, et al. Focal therapy for localized unifocal and multifocal prostate cancer: A prospective development study. *Lancet Oncol* 2012;13:622-32. [https://doi.org/10.1016/S1470-2045\(12\)70121-3](https://doi.org/10.1016/S1470-2045(12)70121-3)
33. Oishi M, Gill IS, Tafuri A, et al. Hemi-gland cryoablation of localized low, intermediate and high-risk prostate cancer: Oncologic and functional outcomes at 5 years. *J Urol* 2020;202:1188-98. <https://doi.org/10.1097/JU.0000000000000456>
34. Bahn DK, Silverman PD. Focal cryoablation of prostate: a review. *Sci World J* 2008;8:486-91. <https://doi.org/10.1100/tsw.2008.56>
35. Azzouzi AR, Barret E, Bennet J, et al. TOOKAD® Soluble focal therapy: Pooled analysis of three phase 2 studies assessing the minimally invasive ablation of localized prostate cancer. *World J Urol* 2015;33:945-53. <https://doi.org/10.1007/s00345-015-1505-8>
36. Azzouzi AR, Vincendeau S, Barret E, et al. Padeliporfin vascular-targeted photodynamic therapy versus active surveillance in men with low-risk prostate cancer (CLIN1001 PCM301): An open-label, phase 3, randomised controlled trial. *Lancet Oncol* 2017;18:181-91. [https://doi.org/10.1016/S1470-2045\(16\)30661-1](https://doi.org/10.1016/S1470-2045(16)30661-1)
37. Van de Bos W, Jurhill RR, de Bruin DM, et al. Histopathological outcomes after irreversible electroporation in the focal treatment of prostate cancer. *Prostate Cancer Prostatic Dis* 2014;17:343-7
38. Van de Bos W, Scheltema MJ, Siriwardana AR, et al. Focal irreversible electroporation as primary treatment for localized prostate cancer. *BJU Int* 2018;121:716-24. <https://doi.org/10.1111/bju.13983>
39. Blazevski A, Scheltema MJ, Yuen B, et al. Oncological and quality-of-life outcomes following focal irreversible electroporation as primary treatment for localized prostate cancer: A biopsy-monitored prospective cohort. *Eur Urol Oncol* 2020;3:283-90. <https://doi.org/10.1016/j.euo.2019.04.008>
40. Scheltema MJ, van den Bos W, Siriwardana AR, et al. Feasibility and safety of focal irreversible electroporation as salvage treatment for localized radio-recurrent prostate cancer. *BJU Int* 2017;120:51-8. <https://doi.org/10.1111/bju.13991>
41. Sherar MD, Gertner MR, Yue CK, et al. Interstitial microwave thermal therapy for prostate cancer: method of treatment and results of a phase 1/2 trial. *J Urol* 2001;166:1707-14. [https://doi.org/10.1016/S0022-5347\(05\)65658-3](https://doi.org/10.1016/S0022-5347(05)65658-3)
42. Barry-Delongchamps N, Schull A, Anract J, et al. Feasibility and safety of targeted focal microwave ablation of the index tumor in patients with low to intermediate risk prostate cancer: Results of the FOSTINE trial. *PLoS One* 2021;16:e0252040. <https://doi.org/10.1371/journal.pone.0252040>
43. Boku H, Kaneko M, Yamada Y, et al. Microwave focal therapy of prostate cancer: a non-clinical study and exploratory clinical trial. *BJU Int* 2022;130:776-85. <https://doi.org/10.1111/bju.15749>
44. Sherar MD, Trachtenberg J, Davidson SR, et al. Interstitial microwave thermal therapy and its application to the treatment of recurrent prostate cancer. *Int J Hyperthermia* 2004;20:757-68. <https://doi.org/10.1080/02656730410001734146>
45. Ramsay E, Mougnot C, Staruch R, et al. Evaluation of focal ablation of magnetic resonance imaging defined prostate cancer using magnetic resonance imaging controlled transurethral ultrasound therapy with prostatectomy as the reference standard. *J Urol* 2017;197:255-61. <https://doi.org/10.1016/j.juro.2016.06.100>
46. Chin JL, Billia M, Relle J, et al. Magnetic resonance imaging-guided transurethral ultrasound ablation of prostate tissue in patients with localized prostate cancer: A prospective phase 1 clinical trial. *Eur Urol* 2016;70:447-55. <https://doi.org/10.1016/j.eururo.2015.12.029>
47. Klotz L, Pavlovich CV, Chin JL, et al. MRI-guided transurethral ultrasound ablation of prostate cancer. *J Urol* 2020. <https://doi.org/10.1097/>
48. Lumiani A, Samun D, Sroka R, Muschter R. Single center retrospective analysis of fifty-two prostate cancer patients with customized MR-guided transurethral ultrasound ablation (TULSA). *Urol Oncol* 2021;39:830.e9-830.e16. <https://doi.org/10.1016/j.urolonc.2021.04.022>
49. Anttinen M, Mäkelä P, Viitala A, et al. Salvage magnetic resonance imaging-guided transurethral ultrasound ablation for localized radio-recurrent prostate cancer: 12-month functional and oncological results. *Eur Urol Open Sci* 2020;22:79-87. <https://doi.org/10.1016/j.euros.2020.10.007>
50. Arroyeh E, Westphalen AC, Kurhanewicz J, et al. Does local recurrence of prostate cancer after radiation therapy occur at the site of primary tumor? Results of a longitudinal MRI and MRSI study. *Int J Radiat Oncol Biol Phys* 2012;82:e787-93. <https://doi.org/10.1016/j.ijrobp.2011.11.030>
51. Jerezek-Fossa BA, Beltramo G, Fariselli L, et al. Robotic image-guided stereotactic radiotherapy, for isolated recurrent primary, lymph node or metastatic prostate cancer. *Int J Radiat Oncol Biol Phys* 2012;82:889-97. <https://doi.org/10.1016/j.ijrobp.2010.11.031>
52. Mbeutcha A, Chauveinc L, Bondiau PY, et al. Salvage prostate re-irradiation using high-dose-rate brachytherapy or focal stereotactic body radiotherapy for local recurrence after definitive radiation therapy. *Radiat Oncol* 2017;12:1-10. <https://doi.org/10.1186/s13014-017-0789-9>
53. Pasquier D, Martinage G, Janoray G, et al. Salvage stereotactic body radiation therapy for local prostate cancer recurrence after radiation therapy: A retrospective, multicenter study of the GETUG. *Int J Radiat Oncol Biol Phys* 2019;105:727-34. <https://doi.org/10.1016/j.ijrobp.2019.07.012>
54. Sivaraman A, Barret E. Focal therapy for prostate cancer: an "à la carte" approach. *Eur Urol* 2016;69:973-5. <https://doi.org/10.1016/j.eururo.2015.12.015>

CORRESPONDENCE: Dr. Joseph L. Chin, Division of Surgical Oncology, Western University, London, ON, Canada; joseph.chin@hsc.on.ca

Visit <https://www.cua.org/UROpedia> to complete the multiple-choice questionnaire associated with this article. This program is an Accredited Self-Assessment Program (Section 3) as defined by the Maintenance of Certification Program of The Royal College of Physicians & Surgeons of Canada, and approved by the Canadian Urological Association. You may claim a maximum of 1 hour of credit.